


Profound Hyponatremia due to Central Diabetes Insipidus in a child with lobar holoprosencephaly

Aravinthan B¹, Srisaravanapavananthan N¹, Kesavan V¹

¹Teaching Hospital Jaffna.

Corresponded Author: Aravinthan, B.
b.aravinthan@gmail.com

 <https://orcid.org/0000-0001-9734-6937>

Abstract

This case report presents a rare endocrine disorder highlights the significance of serum electrolyte measurement in children with congenital brain abnormalities presenting with convulsion. It also emphasizes the importance of careful urine volume estimation in diapered infants suspected to have polyuria.

(Key Words : Central Diabetes Insipidus polyuria hyponatremia)

Introduction

Diabetes insipidus (DI) is characterized by polyuria due to decreased water reabsorption by the collecting tubule. It is caused by either decreased secretion of antidiuretic hormone (central DI) or resistance to its action at the renal level (nephrogenic DI). Central DI can result from multiple etiologies. Congenital brain abnormalities such as optic nerve hypoplasia syndrome with agenesis of the corpus callosum, holoprosencephaly, and familial pituitary hypoplasia may be associated with central DI. Empty sella syndrome, possibly resulting from unrecognized pituitary infarction can be associated with DI in children.(1,2)

The degree of polyuria is primarily determined by the degree of Anti Diuretic Hormone(ADH) lack or resistance. Serum osmolality of >300 mOsm/kgH₂O and urine osmolality of <300 mOsm/kgH₂O in the presence of polyuria, polydipsia and hyponatremia (sodium concentration >145 mmol/L) sets the stage for diagnosis. Treatment includes liberal intake of nutritive fluids. Desmopressin for central DI and thiazide diuretics in nephrogenic DI are the primary pharmacologic options. Polyuria being the earliest clinical clue to diagnosis requires precise quantification. (3) We present a case of central DI in whom polyuria was not recognized by the mother and was only confirmed after careful urine collection. (3)

Holoprosencephaly is a rare developmental abnormality of forebrain (1:13 000-1:16 000 of

births). There are three forms of holoprosencephaly: alobar, semilobar and lobar, identified by brain Magnetic Resonance Imaging (MRI). (4)

Endocrinopathies, such as diabetes insipidus, hypothyroidism, hypocortisolism, and growth hormone deficiency, are frequently associated with holoprosencephaly.

Case Report

A 4 months old baby girl presented with left sided focal afebrile convulsions which lasted for nearly one hour at home. On admission, convulsion had settled, but baby was irritable and had intermittent breath holding episodes.

She was born by normal vaginal delivery, her birth weight was 3.4kg and OFC was 38 cm, At one month of age and the OFC increased to 45 cm. An Ultra sound brain revealed lobar holoprosencephaly associated with fused thalamus which was confirmed by non contrast computed tomography brain.

On examination, she had hypertonia more on lower limbs than upper limbs and unable to hold her neck straight. Her growth parameters were less than 3rd percentile. Occipito -frontal circumference was above the 95th percentile. Her Blood pressure and systemic examination was normal.

Investigations revealed a hyponatremic state (serum sodium 172 mmol/ L) with normal potassium(4.5 mmol/L) and glucose levels(95mg/dl).

After correction , serum sodium declined to 169 mmol/ L but it never reached to the normal range.

Total urine output in 24 hours was 662 ml (2.06L/ m²/hour) indicating polyuria (defined as urine volume ≥ 2 L/ m²/ 24 hours). Further investigations revealed a serum osmolality of 310 mosm/L and urinary osmolality of 49 mosm/L. The very low urinary osmolality in the presence of high serum osmolality accompanied by polyuria confirmed the diagnosis of diabetes insipidus. A vasopressin/



This is an open-access article distributed under the terms of the Creative Commons Attribution 4.0 International License, which permits unrestricted use, distribution and reproduction in any medium provided the original author and source are credited.

desmopressin stimulation test was not performed in this infant due to her small stature. Instead, a trial of treatment with intra nasal desmopressin 10 µg/day was started to help differentiate between nephrogenic and central DI. After 2 days of therapy, her polyuria and serum sodium improved considerably, confirming the diagnosis of central diabetes insipidus.

| Investigations | Before desmopressin | After desmopressin |
|------------------|-------------------------------|-------------------------------|
| Serum Na | 169 mmol/L | 148 mmol/L |
| Urine Na | 12 mmol/L | 77 mmol/L |
| Serum osmolality | 338mOsmol /KgH ₂ O | 304mOsmol /KgH ₂ O |
| Urine osmolality | 49mOsmol /KgH ₂ O | 639mOsmol /KgH ₂ O |

Table 1: Investigations before and after desmopressin treatment



Figure 1: Non Contrast Computed Tomography scan showing Lobar holoprosencephaly with fused Thalamus

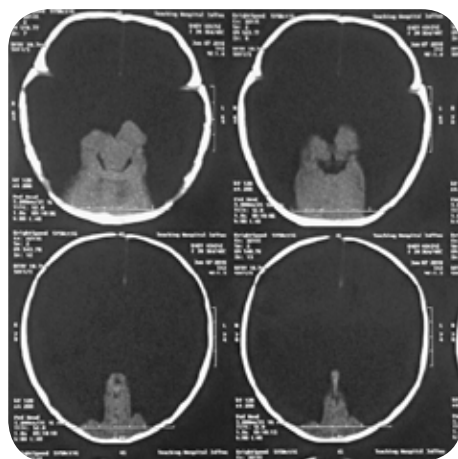


Figure 2: Photograph of the infant showing macrocephaly

Discussion

Polyuria may go unnoticed by caregivers particularly in diapered children. Infants may present with irritability, failure to thrive, and intermittent fever. In severe and untreated cases

altered sensorium ranging from sleepiness to coma may occur. (3)

The diagnosis of diabetes insipidus requires a high index of suspicion especially in infants. Urine volume measurement is mandatory to confirm or exclude pathological polyuria .

Once pathologic polyuria is established, urine specific gravity, serum and urine osmolality, serum electrolytes, blood urea , creatinine glucose, and calcium are determined. Based on serum and urine osmolality the diagnosis of DI is established. (3)

The water deprivation test is also needed to differentiate central from nephrogenic diabetes insipidus. Water restriction is not performed in very young infants. The preferred diagnostic test in this setting is the administration of desmopressin. Patients with the central DI usually achieve a urine osmolality of 300 mOsmol/kg H₂O or higher after desmopressin administration, while patients with nephrogenic DI continue to pass hypo osmolar urine. (3)

Ethical Consideration

Consent was obtained from parents to publish the photograph of the child.

References

1. Kliegman R, Stanton B, St. Geme J, Schor N *et al.* Nelson's textbook of paediatrics.20th ed.2015, chapter 558 : 2644-45.
2. Neil McIntosh , Peter J. Helms, [Rosalind L. Smyth MA](#) , Forfar & Arneil's textbook of paediatrics7thed. 461-62
3. Abeer Vaqar, Asim Rafiq, Khalid Hussain Javid, Rashida Parveen and Rabia Sadaf. Profound Hyponatremia due to Central Diabetes Insipidus. Journal of the College of Physicians and Surgeons Pakistan 2012, Vol. 22 (6): 409-411
4. [Hashim Javad](#),[Saif Al-Yarubi](#), [Alexander P. Chacko](#),[Dilip Sankhla](#),[Amna Al-Futasi](#) *et al.* Semilobar Holoprosencephaly with Neurogenic Hyponatremia.[Sultan Qaboos Univ Med J.](#) 2013 Aug; 13(3): E463–E466. Published online 2013 Jun25.
5. Tom Lissauer, Will Carroll. Illustrated Textbook of Paediatrics.5th ed,2017